

DL METHADONE TREATMENT AGAINST CANCER IN COMBINATION WITH CHEMOTHERAPY

Dr.Claudia Friesen: Head of Molecular Biological Research Center Department of Oncology, University Ulm, Germany

claudia.friesen@uni-ulm.de

Phone: ++49 731 500 65080

Cancer cells express strong opioid receptors on their surface. Opioid receptor activation enhances opioid binding such as DL Methadone. Extensive research has shown better effectivity of chemo-therapy combining DL Methadone

Methadone 1% 100g

Methadone hydrochloride 1g

Kaliumsorbate 0,14g

Zitronensäure (Citric acid) 0,07 g

Aqua pure ad 100g

Dosage DL Methadone 2x35 drops (2x17,5 mg)

Good results also in peritoneal carcinosis together with MTX (Dr.Hilscher) Malign ascites and pleura effusion completely in remission.

Below:

47 year old female with metastatic breast cancer (liver and bone) without DL Methadone and with Methadone leading to full remission

Below: Patient 47 years.

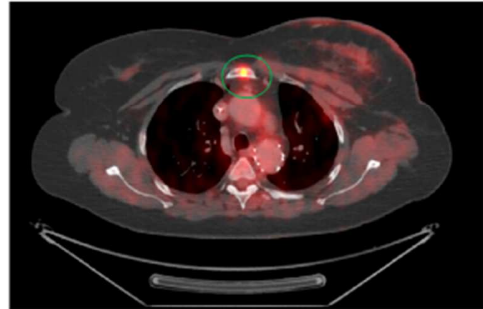
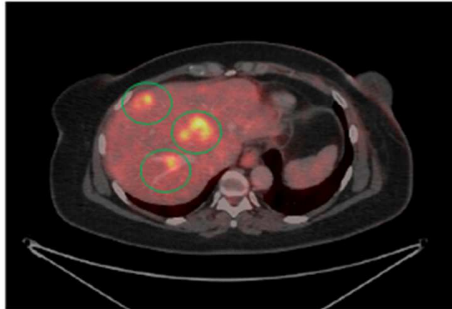
Diagnosis: Metastatic mamma carcinoma in liver and bones. Treatment without and with DL Methadone. Complete remission.

Patientin 47 Jahre

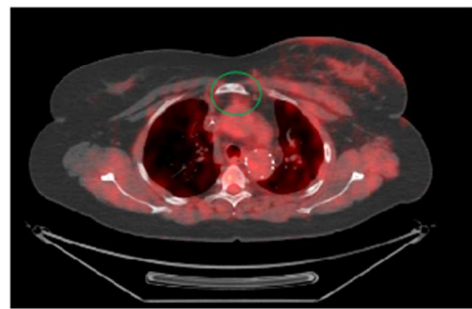
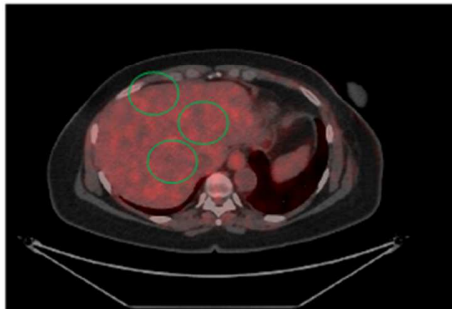
Diagnose: Metastasiertes Mamma Ca

Metastasen: Leber, Knochen

Ohne
D,L-Methadone



Xeloda+ Xgeva
D,L-Methadone



10.2016 Komplettremission

Metastatic pancreatic carcinoma before and after DL Methadone

Second patient:

Diagnosis: Pancreatic carcinoma metastasized

01.2015: Disseminated metastases in liver (4-6cm) only palliative chemotherapy

CA-19-9: 7860

CEA: 1250

01.2015: D, L Methadone + palliative chemotherapy (Gemcitabin)

18.3.2015: **CA 19-9: 502**

31.3.2015: **CEA: 229**

31.3.2015: only a few metastases in liver (with maximum 1 cm)

Patient receives another 4 cycles of chemotherapy

Patient

Diagnose: Pankreaskarzinom, metastasiert

01.2015: Pankreaskarzinom mit disseminierten Lebermetastasen (Größe 4-6 cm),

nur palliative Chemo

C19-9: 7860

CEA: 1250

01.2015: D,L-Methadon + palliative Chemo (Gemcitabin)

18.03.15: **C19-9: 502**

31.03.15: **CEA: 229**

31.03.15: nur noch einzelne Metastasen in der Leber (Größe maximal 1 cm)

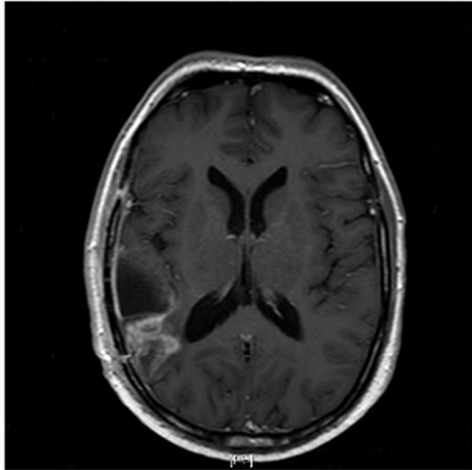
Erhält noch weitere 4 Zyklen Chemo

Patient 49 Jahre

Diagnose: Glioblastoma multiforme IV, MGMT negativ

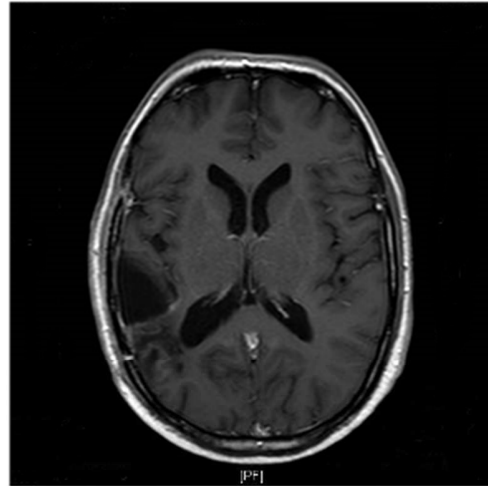
06.12.2014

Temodal



23.01.2015

Temodal + D,L-Methadon



Seit 06.12.2014 D,L-Methadon